

# Natural Integration of a CAD/CAM-Fabricated Full-Coverage Anterior Crown

A 55-year-old female presented for **aesthetic enhancement**. Following radiographic evaluation, a comprehensive treatment plan was developed.

Full-coverage crowns would be placed for teeth #14 and #19; an **all-ceramic crown was required for tooth #9** following orthodontic realignment to adjust spacing in the anterior region.

Tooth whitening was performed to **ensure optimal shade development**.

Shade matching between the **CAD/CAM restoration** and the surrounding dentition were critical.

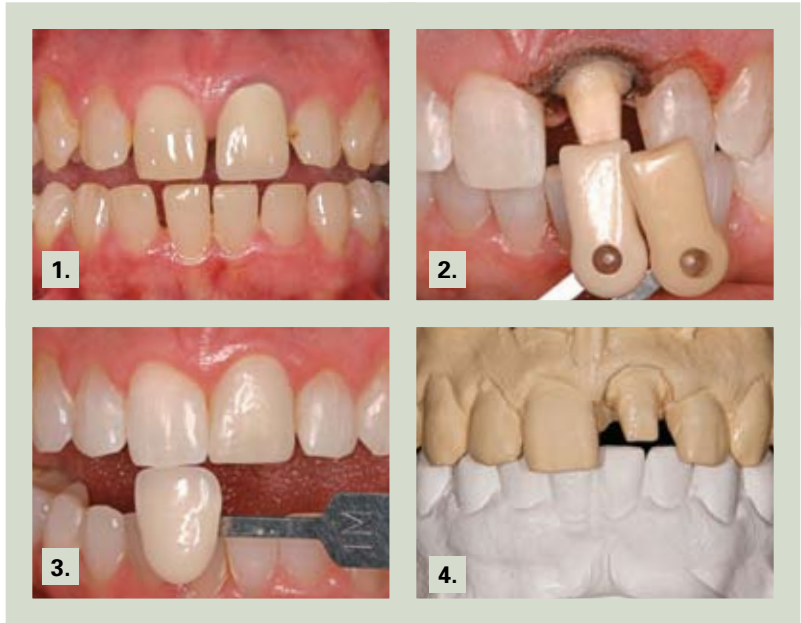

**Steve Hoofard, CDT\***  
**Scott Wehrkam, DDS†**

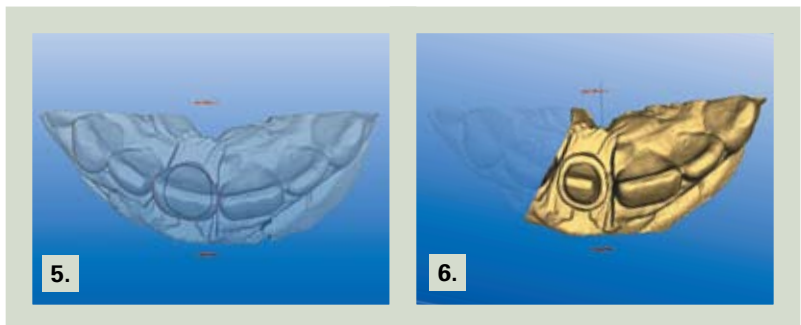\*Laboratory technician,  
Hermiston, Oregon.

†Private practice, Brandon,  
South Dakota.

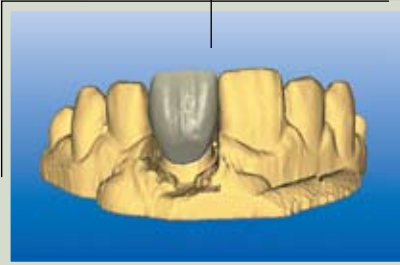
Aesthetic Designs Laboratory  
1050 W. Elm Avenue, Suite 260  
Hermiston, OR 97838  
Tel: 541-567-1667  
E-mail: steveadl@charter.net



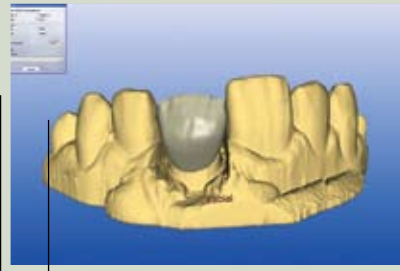
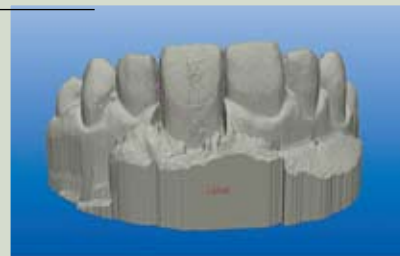
1. Preoperative evaluation demonstrated discoloration in the metal-ceramic crown.
2. The stump shade was measured for ceramic block selection. A traumatic crown lengthening was performed using a diode laser.
3. The shade of the adjacent incisor was also measured.
4. Study models were developed to assist with the initial treatment planning.
5. The inLab System (Sirona, Charlotte, NC) was used to determine the biological parameters required for restoration.
6. The margin for the all-ceramic restoration was identified using the CAD/CAM software.



7. The extensive library of the inLab System (Sirona, Charlotte, NC) enabled simple selection of tooth shape prior to custom design in the dental laboratory.

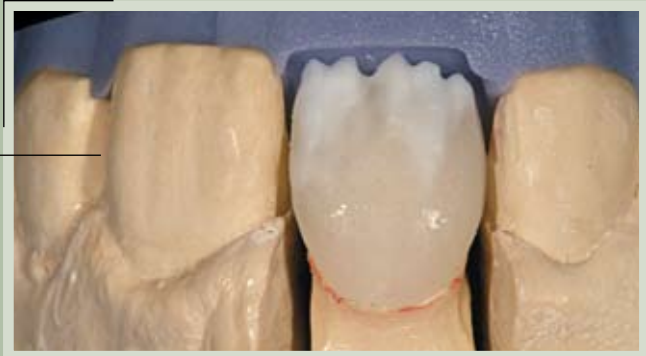

8. The waxup and aesthetic contours were developed using the virtual model.

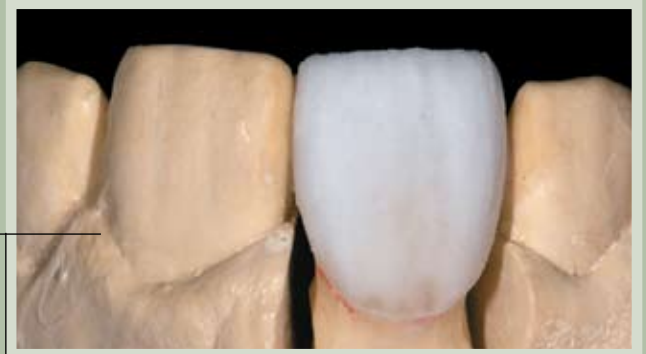

9. The virtual CEREC model helped determine the amount of cutback that would be required during final porcelain layering.


11. Incisal cutback was performed and initial layering commenced following the application of internal stains.



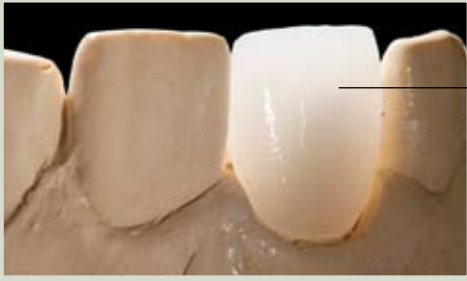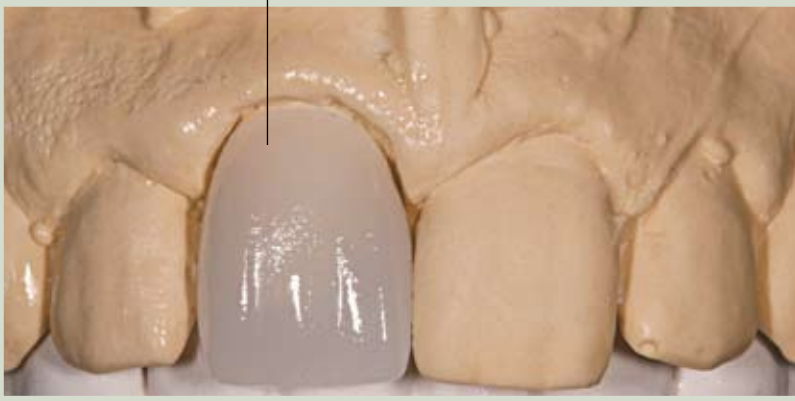12. Enamel shades (IPS Empress, Ivoclar Vivadent, Amherst, NY) were applied to full contour.



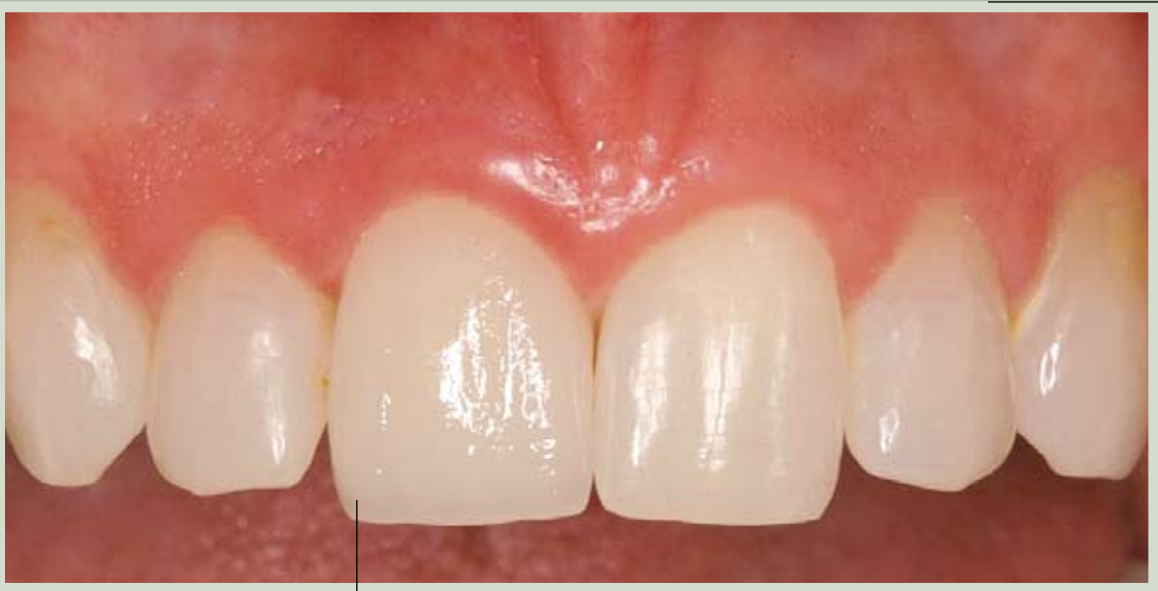10. A leucite-reinforced glass-ceramic block (IPS Empress CAD, Ivoclar Vivadent, Amherst, NY) was used during the milling phase to create the initial substructure for the restoration.



13. Note the aesthetic luster and light reflection evidenced in the definitive restoration.



14. Light transmission was evaluated to ensure optimal translucency prior to delivery.



15. The definitive CAD/CAM restoration was seated. Note the aesthetic integration delivered by the inLab restoration intraorally.